

# Vascular endothelial growth factor and age-related macular degeneration: from basic science to therapy

Napoleone Ferrara

It is almost intuitive that blood vessels have a central role in biology and medicine. Indeed, even though the concept of blood circulation was not established until a few centuries ago, mankind had known for millennia that blood vessels are indispensable for bringing nourishment to organs and limbs. The converse notion—that growth of blood vessels can promote or facilitate disease—is much more recent. Starting in the mid-nineteenth century, several investigators, including Rudolf Virchow, noted that tumor growth is frequently accompanied by increased vascularity<sup>1</sup>. Major conceptual advances took place in the 1930s and 1940s, when it was hypothesized that the ability to induce new vessel growth through release of vasoproliferative factors confers a growth advantage on tumor cells<sup>2,3</sup>.

At about the same time, seminal observations implicating blood-vessel growth in intraocular disorders leading to blindness were made. In 1948, Isaac Michaelson proposed, on the basis of his elegant embryologic and clinicopathological studies, that a diffusible factor (named afterward ‘factor X’) could be responsible not only for the development of the normal retinal vasculature but also for pathological neovascularization in proliferative diabetic retinopathy and other disorders<sup>4</sup>.

Later on, Judah Folkman’s hypothesis that antiangiogenesis could be a strategy to treat cancer and possibly other disorders<sup>5</sup> generated a great deal of enthusiasm and gave a major boost to the field. However, harnessing such therapeutic potential first required the isolation, sequencing and cDNA cloning of the

mediators of angiogenesis, a major technological challenge in those days.

## From neuroendocrinology to angiogenesis and vascular endothelial growth factor

I studied Medicine at the University of Catania Medical School, in the homonymous southern Italian city. It was a fortunate circumstance that Umberto Scapagnini had recently joined our medical school as chairman of pharmacology. Attending his lectures planted the seed for my future career. Scapagnini had made important contributions to neuroendocrinology after spending several years at the University of California–San Francisco (UCSF) in the lab of William Ganong, one of the pioneers in this field. While still a medical student, I joined Scapagnini’s group. Wishing to pursue research in the same field, in 1983 I began a postdoctoral fellowship in Richard Weiner’s laboratory in the Reproductive Endocrinology Center at UCSF.

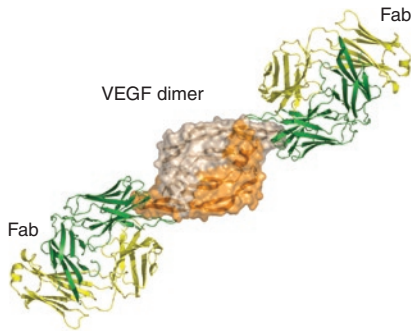
While culturing different cell types from bovine pituitary, I stumbled on a population of non-hormone-secreting cells with unusual characteristics<sup>6</sup>. We identified these cells as follicular cells. The function of follicular cells was poorly understood, but their cytoplasmic projections establish intimate contacts with perivascular spaces, a finding that led some early investigators to suggest that these cells have a role in regulating growth or maintenance of the pituitary vasculature. I was so intrigued by this possibility that I tested follicular cell-conditioned medium on cultured endothelial cells. To my delight, the medium strongly promoted endothelial cell growth<sup>7</sup>. At that time, basic fibroblast growth factor (bFGF) was thought to be the major endothelial cell mitogen and angiogenic factor in pituitary and other organs. However, in 1986 it became known that bFGF is an intracel-

lular protein, because of its lack of secretory signal peptide<sup>8</sup>. This finding caused several investigators to doubt that a protein with such characteristics could regulate angiogenesis, a process that requires diffusion in the environment and generation of gradients. I speculated that the endothelial cell mitogenic activity in the follicular cell-conditioned medium may be due to a secreted protein. I then pursued the isolation of this molecule, hoping that it would prove to be a key player in angiogenesis.

In 1988, I joined Genentech as a research scientist. Given my background in endocrinology, I participated in the development of relaxin, a hormone thought to facilitate parturition. The company has a policy of allowing some time for discretionary research, and I took advantage of this opportunity to work on my favorite project. I was fortunate to find at Genentech not only state-of-the-art technology but also great colleagues and collaborators, including Bill Henzel, David Leung and Dave Goeddel. In 1989, we obtained the amino-terminal amino acid sequence of the purified endothelial mitogen and found that it did not match any known sequence in available databases. Because this protein had selective growth-promoting effects on vascular endothelial cells, I proposed the term ‘vascular endothelial growth factor’ (VEGF)<sup>9</sup>. We then isolated bovine and human cDNA clones encoding VEGF<sup>10</sup>. We identified three different human clones encoding mature proteins of 121, 165 and 189 amino acids, respectively (VEGF<sub>121</sub>, VEGF<sub>165</sub>, VEGF<sub>189</sub>)<sup>10</sup>. Importantly, a typical secretory signal sequence preceded the amino terminus, confirming that VEGF is a secreted protein.

After our cloning paper was accepted for publication<sup>10</sup>, we learned, to our surprise, that a group at Monsanto Company led by Daniel Connolly had submitted at about the

Napoleone Ferrara is at Genentech, South San Francisco, California, USA.  
e-mail: nf@gene.com



**Figure 1** Structure of the VEGF-ranibizumab complex, showing two Fab molecules binding the symmetrical poles of the VEGF dimer<sup>40</sup>. Compared to the bevacizumab Fab, ranibizumab has five residue changes in the variable domains and one in the constant region.

same time a manuscript reporting the cloning of vascular permeability factor (VPF)<sup>11</sup>. These investigators described a human clone that encoded a protein identical to one of the isoforms that we identified—VEGF<sub>189</sub>. Connolly and colleagues had followed up on the elegant early work by Harold Dvorka at Beth Israel Hospital in Boston, who identified VPF as a protein that increases vascular permeability in the skin<sup>12</sup>. However, because VPF had not been purified to homogeneity and sequenced, its identity remained unknown<sup>12</sup>.

**Establishing the role of VEGF in angiogenesis**

The cloning of VEGF (known also as VEGF-A following the discovery of several family members—VEGF-B, VEGF-C, VEGF-D and placenta growth factor) as an angiogenic and a permeability-enhancing factor generated considerable interest in the field<sup>1</sup>. However, much more research was needed before anyone could conclude that VEGF is a physiologically relevant molecule, let alone a therapeutic target. But early studies already suggested that we were on the right track. The VEGF isoforms appeared remarkably well suited to generate biochemical gradients, a requirement for angiogenesis *in vivo*, owing to their differential affinity for heparan sulfate proteoglycans in the cell surface and extracellular matrix, which in turn determined their diffusibility<sup>13,14</sup>.

The identification of the VEGF receptors enabled important advances in the understanding of VEGF action. In 1992, in collaboration with Lewis Williams at UCSF, we identified the Flt-1 tyrosine kinase<sup>15</sup> (presently known as VEGFR-1) as a high-affinity VEGF receptor<sup>16</sup>. Subsequently, a highly homologous tyrosine kinase was identified as VEGFR-2 by Bruce Terman and his colleagues at American Cyanamid<sup>17</sup>. It has become clear that VEGFR-

2, in spite of its lower binding affinity for VEGF, is the main signaling receptor, whereas VEGFR-1 has highly complex and context-dependent roles<sup>18</sup>.

To elucidate the role of VEGF *in vivo*, we developed a series of pharmacological and genetic tools to inhibit its function. In 1993, we reported that administration of a VEGF-specific monoclonal antibody substantially reduced growth of several human tumor cell lines implanted in immunodeficient mice<sup>19</sup>. These studies resulted in the clinical development of a humanized variant of this VEGF-specific antibody<sup>20</sup> (bevacizumab), which has been approved for therapy of multiple tumor types<sup>21</sup>.

Structural and functional studies of VEGFR-1 led to the discovery that, of the seven extracellular immunoglobulin-like domains, domain 2 is the crucial element for high-affinity VEGF binding<sup>22</sup>. This finding enabled the design of chimeric soluble receptors (known also as ‘VEGF traps’) as potent inhibitors that, unlike many monoclonal antibodies, can block VEGF across species. The availability of these tools allowed us to establish the role of VEGF in angiogenesis associated with some crucial physiological processes such as organ and skeletal growth<sup>23,24</sup> and differentiation of the ovarian corpus luteum<sup>25</sup>. Inactivation of the *Vegfa* gene in mice provided evidence for the indispensable role of this molecule in the development of the vasculature and revealed that loss of even a single *Vegfa* allele results in early embryonic lethality<sup>26,27</sup>.

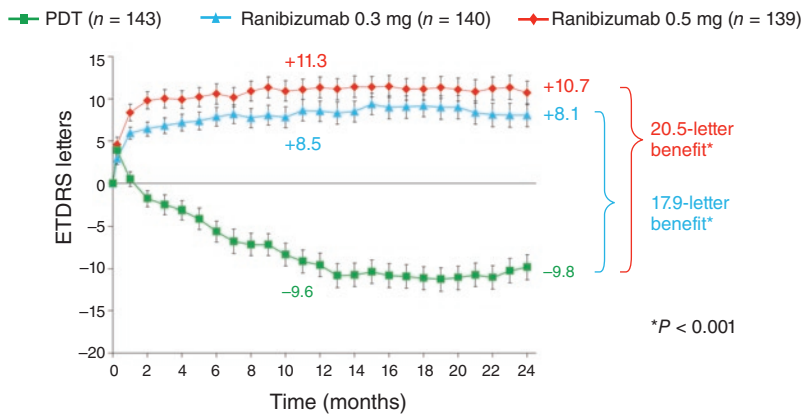
**VEGF is a mediator of intraocular neovascularization**

By the early 1990s, it became clear that VEGF has several features consistent with those of

factor X, including diffusibility and hypoxia inducibility<sup>28</sup>. So several groups converged on this molecule as a potential mediator of retinal ischemia-related neovascularization. In 1994, in a collaborative study with Lloyd Aiello and George King at the Joslin Diabetes Center in Boston, we found a striking correlation between VEGF concentrations, measured in the eye fluids from 164 patients, and active proliferative retinopathy associated with diabetes, occlusion of central retinal vein or prematurity<sup>29</sup>. Tony Adamis and colleagues at Massachusetts Eye and Ear Infirmary in Boston also reported elevated VEGF amounts in the vitreous of individuals with diabetic retinopathy<sup>30</sup>.

Meanwhile, it became known that VEGF upregulation in the eye is not limited to ischemic retinal disorders. The localization of VEGF in choroidal neovascular membranes from individuals with neovascular (wet) age-related macular degeneration (AMD)—the leading cause of irreversible severe vision loss in the older adult population—was reported<sup>31,32</sup>. Choroidal neovascularization (CNV), which results in vision-impairing exudation and hemorrhage, is a prominent feature of wet AMD and affects the macula, a photoreceptor-dense area in the central portion of the retina that is responsible for central, high-resolution vision<sup>33</sup>.

Proof-of-concept studies supported the hypothesis that VEGF is a major player in intraocular neovascularization. Administration of chimeric soluble VEGF receptors markedly reduced retinal neovascularization in a mouse model of retinopathy prematurity<sup>34</sup>. Also, in collaboration with Tony Adamis and Joan Miller, we tested the effects of human VEGF-specific monoclonal antibody in a primate model of iris



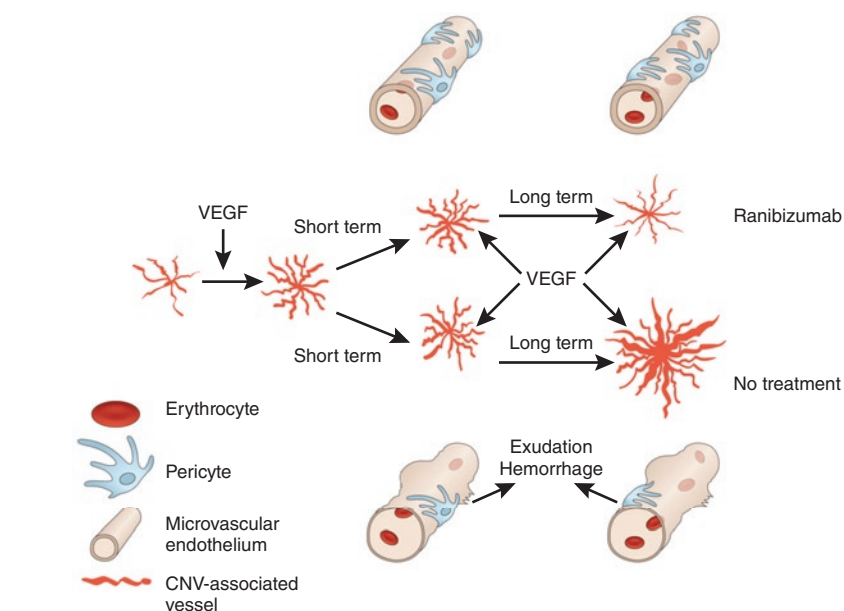
**Figure 2** Mean change from baseline visual acuity score (letters) over time in the ANCHOR trial. Subjects with predominantly classic CNV were randomized to the indicated treatment groups: PDT alone or 0.3 or 0.5 mg ranibizumab. Vertical bars represent s.e.m. Note the dose response in the effects of ranibizumab. ETDRS, Early Treatment Diabetic Retinopathy Study (Box 1). Figure modified from ref. 44.

neovascularization caused by central retinal vein occlusion, taking advantage of the complete identity between human and simian VEGF proteins. The treatment resulted in a nearly complete inhibition of blood-vessel growth<sup>35</sup>. Additional VEGF pathway inhibitors were also shown to inhibit intraocular neovascularization in a variety of models<sup>36</sup>.

### Developing an anti-VEGF therapy for wet AMD

The primary clinical target of our VEGF-specific antibody programs was cancer. Wet AMD was also an exciting indication, given the unmet medical need. Indeed, although the wet form accounts for about 10–20% of AMD cases, it is responsible for 80–90% of the severe vision loss associated with AMD<sup>37</sup>. About 200,000 new cases of wet AMD are diagnosed each year in the US. Although laser photocoagulation is an effective treatment for proliferative diabetic retinopathy, few options were available at that time for wet AMD (**Box 1**).

However, developing a VEGF-specific antibody therapy for wet AMD presented considerable challenges<sup>38</sup>. It was unclear to what extent the animal models of CNV replicated the pathogenesis of AMD. Also, the optimal route of administration needed to be established. We initially considered testing the intravenous administration of bevacizumab, but the possibility of cardiovascular adverse events in an elderly population, such as that of people with AMD, led us to conclude that the intraocular route of administration



**Figure 3** Role of VEGF in the progression of CNV in wet AMD. Uncontrolled VEGF expression results in growth of new blood vessels, which fail to mature and show a number of abnormalities including tortuosity and reduced numbers of pericytes<sup>49,50</sup>. These structural defects might result in fragility and propensity to exudation and bleeding, which in turn cause photoreceptor damage and vision impairment. The direct permeabilizing effects of VEGF may augment exudation. Reflecting the role of VEGF as a survival factor, VEGF blockade results in rapid vessel remodeling, with regression of pericyte-poor capillaries, reduced lumen diameter and permeability<sup>51–53</sup>. As CNV expands, the amount of exudation and bleeding increases, further impairing vision. Ranibizumab treatment results in complete suppression of CNV growth over at least a two-year period<sup>42–44</sup>.

would be preferable. However, there was a theoretical risk that long-term injection of full-length antibodies in human eyes (which had not been previously done) might trigger complement-mediated or cell-dependent cytotoxicity caused by interaction of the anti-

body with Fc receptors in immune cells<sup>39</sup>. We felt that removing the Fc would be the prudent choice. Furthermore, a variety of studies indicated that antigen-binding fragments (Fabs) have better tissue penetration than full-length antibodies<sup>38</sup>. Therefore, we engineered a Fab

### Box 1 Key clinical features of AMD and therapeutic options before ranibizumab.

The hallmark of AMD is the drusen—focal deposition of debris between the retinal pigment epithelium (RPE) and Bruch's membrane. It is believed that damage to the RPE and chronic inflammation leads to areas of atrophy<sup>33</sup>. Depending of the number and size of drusen and the extent of atrophy, AMD is classified as early, intermediate and advanced<sup>33</sup>. Advanced AMD can be non-neovascular and neovascular (or wet). Key features of wet AMD are CNV and abnormalities such as RPE detachment, fibrovascular scarring and vitreous hemorrhages<sup>54</sup>. Growth of abnormal and fragile vessels (see **Fig. 3**) frequently results in bleeding and fluid leakage, which can in turn cause loss of central vision.

Visual acuity tests are the most common way to measure visual function in wet AMD and other intraocular disorders. They are typically based on the ability to discriminate letters layered in lines of decreasing size. A chart test widely used in clinical research was initially developed for the Early Treatment Diabetic Retinopathy Study<sup>54</sup>. Fluorescein angiography enabled the identification of two major CNV patterns, known as 'classic' and 'occult'<sup>55</sup>. Classic CNV is a discrete and well-demarcated area of hyperfluorescence, especially in the early phases of angiogram. Occult CNV, the most frequent pattern, is characterized by less well-defined borders and leakage. Mixed patterns with different degrees of classic and occult components are common, and classic CNV has a more aggressive clinical course than occult CNV.

Before ranibizumab, the main therapeutic options for patients with wet AMD were laser photocoagulation or surgical resection of CNV. These approaches, however, had limited efficacy and could be used only in selected cases<sup>33</sup>. The advent of ocular PDT represented a therapeutic advance. In PDT, a laser beam focused over the macula is used to activate an intravenously administered, light-sensitive dye (verteporfin) that accumulates in new blood vessels, causing localized choroidal neovascular thrombosis. The safety of this treatment and its reduction of the risk of moderate and severe vision loss, especially in patients with predominantly classic CNV, has been documented<sup>47</sup>. However, PDT results in only transient improvement in visual acuity (see **Fig. 2**).

In 2004, the FDA approved pegaptanib sodium<sup>48</sup> as an intravitreal treatment for wet AMD. Pegaptanib is an aptamer that interacts with the heparin-binding domain of VEGF. Whereas pegaptanib resulted in slowing down of vision loss, few patients experienced improvements in visual acuity<sup>48</sup>, perhaps as a result of the inability of this agent to bind and inhibit the action of non-heparin-binding proteolytic fragments of VEGF that result from the action of matrix metalloproteinase-3 or plasmin<sup>56</sup>.

fragment of bevacizumab to further enhance its binding affinity for VEGF<sup>40</sup> (Fig. 1). In spite of its monovalent binding, this affinity-matured Fab (ranibizumab) is 10–20-fold more potent than bevacizumab at inhibiting VEGF-induced endothelial cell proliferation. Also, intravitreal administration of ranibizumab markedly inhibited vascularization and leakage in a primate model of CNV<sup>41</sup>.

### Ranibizumab pivotal trials

Genentech initiated clinical trials in subjects with neovascular AMD in February 2000. After encouraging data from phase 1 and phase 2 studies, we proceeded to study ranibizumab in phase 3 trials. Two randomized, double-blind controlled trials in different populations of individuals with AMD (the MARINA trial and the ANCHOR trial) resulted in the approval of ranibizumab by the US Food and Drug Administration (FDA) in June 2006.

The MARINA trial randomized subjects with minimally classic or occult without classic subfoveal CNV to one of three treatment arms: monthly sham injections or monthly intravitreal injections of either 0.3 or 0.5 mg ranibizumab<sup>42</sup>. In the primary analysis at one year, the study met its primary endpoint, with 95% and 96% of subjects in the 0.3-mg and 0.5-mg ranibizumab groups, respectively, losing their ability to detect <15 letters on the eye chart compared with 62% in the sham injection group (Box 1). Also, subjects treated with 0.3 mg and 0.5 mg ranibizumab gained 6.5 letters and 7.2 letters, respectively, whereas subjects in the sham injection group lost an average of 10.4 letters. These visual acuity benefits persisted through the second year of the study.

The ANCHOR trial randomized subjects with predominantly classic CNV to one of three treatment arms: verteporfin photodynamic therapy (PDT) with monthly sham ocular injections and monthly intravitreal injections of either 0.3 or 0.5 mg ranibizumab with a sham PDT procedure<sup>43</sup>. The treatment effects of ranibizumab at one year were similar to those observed in the MARINA trial, despite the presence of an active control (PDT) in the ANCHOR trial and a more aggressive lesion type. A two-year analysis confirmed the persistence of the benefit (Fig. 2)<sup>44</sup>.

Subsequent phase 3 trials showed that ranibizumab improves visual acuity also in subjects with central<sup>45</sup> and branch<sup>46</sup> retinal vein occlusion (the CRUISE and BRAVO trials, respectively), validating the preclinical data implicating VEGF in ischemic retinal diseases<sup>35</sup>. In July 2010, ranibizumab was approved by the FDA for the treatment of retinal vein occlusion.

### Conclusions

I am extremely gratified and humbled that the work that I initiated 25 years ago resulted in a therapy for a condition as devastating as wet AMD. The magnitude of the benefit, particularly the visual-acuity gains, exceeded my expectations, considering that previous treatments only slowed down the rate of vision loss<sup>47,48</sup> (Fig. 2). So far, about 450,000 patients have been treated with ranibizumab (Lucentis) worldwide. An even larger number of people have received bevacizumab off label, although the degree of benefit is unclear, pending the outcome of controlled studies.

Figure 3 illustrates the role of VEGF in the progression of CNV, and the mechanisms of exudation and bleeding in light of recent vascular biology concepts. One aspect that remains less clear is the nature of the changes that lead to progression of early AMD into wet AMD and VEGF upregulation. However, several studies have identified mutations in a number of genes involved in complement activation and immune regulation and point to inflammation as one of the key events in the progression of AMD<sup>33</sup>. Therefore, it is conceivable that tissue damage, leading to hypoxia, is a major factor in VEGF upregulation in AMD.

What is next for wet AMD therapy? Late-stage clinical trials are currently testing other VEGF inhibitors such as bevacizumab and VEGF-Trap. Furthermore, numerous trials are currently exploring a variety of therapeutic agents<sup>33</sup>. This gives hope that combining angiogenesis inhibitors with agents that target additional pathways (involved, for example, in destructive late events such as fibrosis and scarring) or with neurotrophic factors may go beyond the benefits achieved so far from targeting VEGF alone.

### ACKNOWLEDGMENTS

It would be difficult to name all the contributors to a program that began 15 years ago. I thank all the ranibizumab team members. I wish to thank my current and former lab members. I am especially grateful to the following past and present colleagues and collaborators: H. Lowman, L. Presta, A. Cuthbertson, T. Adamis, J. Miller, L. D'Amico, R. Kim, T. Ianchulev & K. Hillan. I also wish to thank the ranibizumab clinical investigators. I thank my wife, Chika, for her understanding and support. I wish to express my sincere gratitude to the Lasker Foundation for conferring on me such a wonderful and prestigious award that I accept on behalf of my colleagues.

### COMPETING FINANCIAL INTERESTS

The author declares competing financial interests: details accompany the full-text HTML version of the paper at <http://www.nature.com/naturemedicine/>.

1. Ferrara, N. VEGF and the quest for tumour angiogenesis factors. *Nat. Rev. Cancer* **2**, 795–803 (2002).
2. Ide, A.G., Baker, N.H. & Warren, S.L. Vascularization of

the Brown Pearce rabbit epithelioma transplant as seen in the transparent ear chamber. *AJR Am. J. Roentgenol.* **42**, 891–899 (1939).

3. Algire, G.H., Chalkley, H.W., Legallais, F.Y. & Park, H.D. Vascular reactions of normal and malignant tissues in vivo. I. Vascular reactions of mice to wounds and to normal and neoplastic transplants. *J. Natl. Cancer Inst.* **6**, 73–85 (1945).
4. Michaelson, I.C. The mode of development of the vascular system of the retina with some observations on its significance for certain retinal disorders. *Trans. Ophthalmol. Soc. U. K.* **68**, 137–180 (1948).
5. Folkman, J. Tumor angiogenesis: therapeutic implications. *N. Engl. J. Med.* **285**, 1182–1186 (1971).
6. Ferrara, N., Fujii, D.K., Goldsmith, P.C., Widdicombe, J.H. & Weiner, R.I. Transport epithelial characteristics of cultured bovine pituitary follicular cells. *Am. J. Physiol.* **252**, E304–E312 (1987).
7. Ferrara, N. Vascular endothelial growth factor. *Arterioscler. Thromb. Vasc. Biol.* **29**, 789–791 (2009).
8. Abraham, J.A. *et al.* Nucleotide sequence of a bovine clone encoding the angiogenic protein, basic fibroblast growth factor. *Science* **233**, 545–548 (1986).
9. Ferrara, N. & Henzel, W.J. Pituitary follicular cells secrete a novel heparin-binding growth factor specific for vascular endothelial cells. *Biochem. Biophys. Res. Commun.* **161**, 851–858 (1989).
10. Leung, D.W., Cachianes, G., Kuang, W.J., Goeddel, D.V. & Ferrara, N. Vascular endothelial growth factor is a secreted angiogenic mitogen. *Science* **246**, 1306–1309 (1989).
11. Keck, P.J. *et al.* Vascular permeability factor, an endothelial cell mitogen related to PDGF. *Science* **246**, 1309–1312 (1989).
12. Senger, D.R. *et al.* Tumor cells secrete a vascular permeability factor that promotes accumulation of ascites fluid. *Science* **219**, 983–985 (1983).
13. Houck, K.A., Leung, D.W., Rowland, A.M., Winer, J. & Ferrara, N. Dual regulation of vascular endothelial growth factor bioavailability by genetic and proteolytic mechanisms. *J. Biol. Chem.* **267**, 26031–26037 (1992).
14. Park, J.E., Keller, G.-A. & Ferrara, N. The vascular endothelial growth factor isoforms (VEGF): differential deposition into the subepithelial extracellular matrix and bioactivity of extracellular matrix-bound VEGF. *Mol. Biol. Cell* **4**, 1317–1326 (1993).
15. Shibuya, M. *et al.* Nucleotide sequence and expression of a novel human receptor-type tyrosine kinase (flt) closely related to the fms family. *Oncogene* **5**, 519–527 (1990).
16. de Vries, C. *et al.* The fms-like tyrosine kinase, a receptor for vascular endothelial growth factor. *Science* **255**, 989–991 (1992).
17. Terman, B.I. *et al.* Identification of the KDR tyrosine kinase as a receptor for vascular endothelial cell growth factor. *Biochem. Biophys. Res. Commun.* **187**, 1579–1586 (1992).
18. Chung, A.S., Lee, J. & Ferrara, N. Targeting the tumour vasculature: insights from physiological angiogenesis. *Nat. Rev. Cancer* **10**, 505–514 (2010).
19. Kim, K.J. *et al.* Inhibition of vascular endothelial growth factor-induced angiogenesis suppresses tumor growth in vivo. *Nature* **362**, 841–844 (1993).
20. Presta, L.G. *et al.* Humanization of an anti-VEGF monoclonal antibody for the therapy of solid tumors and other disorders. *Cancer Res.* **57**, 4593–4599 (1997).
21. Ferrara, N., Hillan, K.J., Gerber, H.P. & Novotny, W. Discovery and development of bevacizumab, an anti-VEGF antibody for treating cancer. *Nat. Rev. Drug Discov.* **3**, 391–400 (2004).
22. Davis-Smyth, T., Chen, H., Park, J., Presta, L.G. & Ferrara, N. The second immunoglobulin-like domain of the VEGF tyrosine kinase receptor Flt-1 determines ligand binding and may initiate a signal transduction cascade. *EMBO J.* **15**, 4919–4927 (1996).
23. Gerber, H.P. *et al.* VEGF is required for growth and survival in neonatal mice. *Development* **126**, 1149–1159 (1999).
24. Gerber, H.P. *et al.* VEGF couples hypertrophic cartilage remodeling, ossification and angiogenesis during endochondral bone formation. *Nat. Med.* **5**, 623–628 (1999).
25. Ferrara, N. *et al.* Vascular endothelial growth factor is

- essential for corpus luteum angiogenesis. *Nat. Med.* **4**, 336–340 (1998).
26. Ferrara, N. *et al.* Heterozygous embryonic lethality induced by targeted inactivation of the VEGF gene. *Nature* **380**, 439–442 (1996).
  27. Carmeliet, P. *et al.* Abnormal blood vessel development and lethality in embryos lacking a single VEGF allele. *Nature* **380**, 435–439 (1996).
  28. Shweiki, D., Itin, A., Soffer, D. & Keshet, E. Vascular endothelial growth factor induced by hypoxia may mediate hypoxia-initiated angiogenesis. *Nature* **359**, 843–845 (1992).
  29. Aiello, L.P. *et al.* Vascular endothelial growth factor in ocular fluid of patients with diabetic retinopathy and other retinal disorders. *N. Engl. J. Med.* **331**, 1480–1487 (1994).
  30. Adamis, A.P. *et al.* Increased vascular endothelial growth factor levels in the vitreous of eyes with proliferative diabetic retinopathy. *Am. J. Ophthalmol.* **118**, 445–450 (1994).
  31. Lopez, P.F., Sippy, B.D., Lambert, H.M., Thach, A.B. & Hinton, D.R. Transdifferentiated retinal pigment epithelial cells are immunoreactive for vascular endothelial growth factor in surgically excised age-related macular degeneration-related choroidal neovascular membranes. *Invest. Ophthalmol. Vis. Sci.* **37**, 855–868 (1996).
  32. Kvantta, A., Alverge, P.V., Berglin, L. & Seregard, S. Subfoveal fibrovascular membranes in age-related macular degeneration express vascular endothelial growth factor. *Invest. Ophthalmol. Vis. Sci.* **37**, 1929–1934 (1996).
  33. Jager, R.D., Mieler, W.F. & Miller, J.W. Age-related macular degeneration. *N. Engl. J. Med.* **358**, 2606–2617 (2008).
  34. Aiello, L.P. *et al.* Suppression of retinal neovascularization *in vivo* by inhibition of vascular endothelial growth factor (VEGF) using soluble VEGF-receptor chimeric proteins. *Proc. Natl. Acad. Sci. USA* **92**, 10457–10461 (1995).
  35. Adamis, A.P. *et al.* Inhibition of vascular endothelial growth factor prevents retinal ischemia-associated iris neovascularization in a nonhuman primate. *Arch. Ophthalmol.* **114**, 66–71 (1996).
  36. Campochiaro, P.A. & Hackett, S.F. Ocular neovascularization: a valuable model system. *Oncogene* **22**, 6537–6548 (2003).
  37. Ferris, F.L., III, Fine, S.L. & Hyman, L. Age-related macular degeneration and blindness due to neovascular maculopathy. *Arch. Ophthalmol.* **102**, 1640–1642 (1984).
  38. Ferrara, N., Damico, L., Shams, N., Lowman, H. & Kim, R. Development of Ranibizumab, an anti-vascular endothelial growth factor antigen binding fragment, as therapy for neovascular age-related macular degeneration. *Retina* **26**, 859–870 (2006).
  39. Raghavan, M. & Bjorkman, P.J. Fc receptors and their interactions with immunoglobulins. *Annu. Rev. Cell Dev. Biol.* **12**, 181–220 (1996).
  40. Chen, Y. *et al.* Selection and analysis of an optimized anti-VEGF antibody: crystal structure of an affinity-matured Fab in complex with antigen. *J. Mol. Biol.* **293**, 865–881 (1999).
  41. Krzystolik, M.G. *et al.* Prevention of experimental choroidal neovascularization with intravitreal anti-vascular endothelial growth factor antibody fragment. *Arch. Ophthalmol.* **120**, 338–346 (2002).
  42. Rosenfeld, P.J. *et al.* Ranibizumab for neovascular age-related macular degeneration. *N. Engl. J. Med.* **355**, 1419–1431 (2006).
  43. Brown, D.M. *et al.* Ranibizumab versus verteporfin for neovascular age-related macular degeneration. *N. Engl. J. Med.* **355**, 1432–1444 (2006).
  44. Brown, D.M. *et al.* Ranibizumab versus verteporfin photodynamic therapy for neovascular age-related macular degeneration: Two-year results of the ANCHOR study. *Ophthalmology* **116**, 57–65 (2009).
  45. Brown, D.M. *et al.* Ranibizumab for macular edema following central retinal vein occlusion: six-month primary end point results of a phase III study. *Ophthalmology* **117**, 1124–1133 (2010).
  46. Campochiaro, P.A. *et al.* Ranibizumab for macular edema following branch retinal vein occlusion: six-month primary end point results of a phase III study. *Ophthalmology* **117**, 1102–1112 (2010).
  47. Treatment of age-related macular degeneration with photodynamic therapy (TAP) Study Group. Photodynamic therapy of subfoveal choroidal neovascularization in age-related macular degeneration with verteporfin. one-year results of 2 randomized clinical trials—TAP Report 1. *Arch. Ophthalmol.* **117**, 1329–1345 (1999).
  48. Gragoudas, E.S., Adamis, A.P., Cunningham, E.T. Jr., Feinsod, M. & Guyer, D.R. Pegaptanib for neovascular age-related macular degeneration. *N. Engl. J. Med.* **351**, 2805–2816 (2004).
  49. Nagy, J.A. *et al.* Permeability properties of tumor surrogate blood vessels induced by VEGF-A. *Lab. Invest.* **86**, 767–780 (2006).
  50. Motiejunaite, R. & Kazlauskas, A. Pericytes and ocular diseases. *Exp. Eye Res.* **86**, 171–177 (2008).
  51. Yuan, F. *et al.* Time-dependent vascular regression and permeability changes in established human tumor xenografts induced by an anti-vascular endothelial growth factor/vascular permeability factor antibody. *Proc. Natl. Acad. Sci. USA* **93**, 14765–14770 (1996).
  52. Benjamin, L.E., Golijanin, D., Itin, A., Pode, D. & Keshet, E. Selective ablation of immature blood vessels in established human tumors follows vascular endothelial growth factor withdrawal. *J. Clin. Invest.* **103**, 159–165 (1999).
  53. Jain, R.K. Normalization of tumor vasculature: an emerging concept in antiangiogenic therapy. *Science* **307**, 58–62 (2005).
  54. Bressler, N.M., Bressler, S.B. & Fine, S.L. Neovascular (exudative) age-related macular degeneration. in *Retina* vol. 2 (ed. Ryan, S.J.) 1075–1113 (Elsevier/Mosby, 2006).
  55. Macular Photocoagulation Study Group. Subfoveal neovascular lesions in age-related macular degeneration. *Arch. Ophthalmol.* **109**, 1242–1257 (1991).
  56. Ferrara, N. Binding to the extracellular matrix and proteolytic processing: two key mechanisms regulating vascular endothelial growth factor action. *Mol. Biol. Cell* **21**, 687–690 (2010).